



## Resistant hypertension in pediatric end stage renal disease

### *Hipertensión resistente en enfermedad renal terminal pediátrica*

#### Introduction

Chronic kidney disease (CKD) is defined as the irreversible loss of kidney function, producing progressive decrease in glomerular filtration up to achieve the so-called end stage renal disease (ESRD)<sup>1</sup>.

The long-term survival in children with ESRD has improved but mortality is still about 30 times higher than expected for age. This increases the need for extreme vigilance to achieve the best therapeutic results with less risk<sup>2</sup>.

According to The National Kidney Foundation Kidney Disease Outcomes Quality Initiative (K/DOQI) guidelines, CKD is classified into five stages of increasing severity<sup>3</sup>. The renal disease progression to ESRD is largely due to secondary factors that may vary, such as hypertension and proteinuria, whose control is vital because it can prevent the progression of kidney damage.

The tight control of blood pressure (BP) is crucial. Initially antihypertensive therapy was performed empirically. Subsequent data in adults suggest superiority of angiotensin converting enzyme (ACE) inhibitors and angiotensin II receptor blockers (ARBs) as compared to other antihypertensive agents (diuretics, calcium channel blockers,  $\beta$ -blockers) resulting in a change of pharmacotherapeutic strategy<sup>4</sup>.

Following the results of the ESCAPE trial<sup>5</sup>, which established the need of strict control of BP, the European Society of Hypertension<sup>6</sup> set new standards in treating hypertension in children with CKD: target of BP of the 75th percentile in patients without proteinuria and of the 50th percentile in children with proteinuria. It is called resistant hypertension when BP is above the target value despite treatment with three antihypertensive drugs<sup>4</sup>.

Proteinuria is not only a marker of kidney disease but also a risk factor for progression of CKD. Data from the European Study Group of Nutritional Treatment of Chronic Renal Failure in Childhood show that urinary protein excretion greater than 60mg/m<sup>2</sup>/h represents a high risk of progression of CKD<sup>7</sup>.

Drugs that block the renin-angiotensin-aldosterone system have shown to reduce proteinuria. Consequently, it has been suggested that even normotensive patients should be treated with ACE inhibitors or ARBs if proteinuria is present<sup>8</sup>.

#### Case Report

Preterm infant admitted for prematurity, peculiar phenotype and suspected fetal distress. After 48 hours of life he became edematous with hyponatremia and albumin of 1.2 g/dl. Renal function was evaluated, with GFR 45 ml/min/73m<sup>2</sup>, proteinuria 92 mg/m<sup>2</sup>/h, creatinine 0.5 mg/dl and urea 22 mg/dl, fulfilling diagnostic criteria for nephrotic syndrome.

The patient required fluid restriction, and transfusions of albumin 0.8 g/kg/day with furosemide 0.5 mg/kg, with which he gradually improved. Captopril 0.2 mg/kg every 8 hours was also initiated. It was well tolerated but with little improvement in proteinuria (47 mg/m<sup>2</sup>/h).

The patient showed persisting high proteinuria, and was stable from a clinical perspective with a tendency to slight palpebral edema without ascites. His diuresis was 2 ml/kg/h. At 6 weeks of age, the patient was discharged from the hospital.

At 2 months of age, the patient required hospital admission from the emergency department due to edema, fever and irritability. Gammaglobulin and infusions of albumin and furosemide were administered. This was well tolerated by the patient, with a decrease in edema. At 7 months of age the patient began to have higher BP values (100/60 mmHg), so spironolactone 3mg every 24 hours was added to captopril. Increased values of creatinine 25.0 mg/dl, and protein 757 mg/dl were identified in urine.

At 9 months of age, the patient had a g-tube placed and remained under permanent clinical follow-up. The progression of the disease led to automated peritoneal dialysis (APD) at 16 months of age. Indomethacin was also initiated, reaching 2.5 mg/kg/day with increased blood albumin and improved ultrafiltration. BP values occasionally improved: 77/48 mmHg.

Despite APD and captopril, the patient continued with proteinuria and hypertension. This was later on replaced by enalapril 0.4 mg/kg/day plus nifedipine 1.5 mg/kg/day, labetalol 8.3 mg/kg/day and nifedipine on demand. Losartan was added to treatment, with limited therapeutic success. Figure 1 shows the evolution of proteinuria (mg/dl) from birth to the onset of automated peritoneal dialysis.

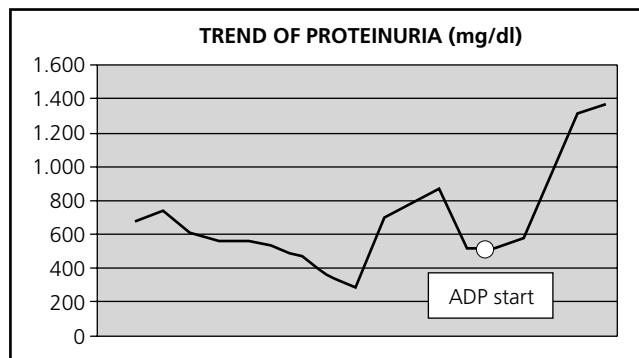
Finally, at 30 months of age, the patient underwent bilateral nephrectomy due to uncontrolled hypertension, thereby stabilizing the BP.

## Discussion

The pharmacotherapeutic approach to the clinical management of this case was based on the recommendations made by the pediatric working groups<sup>5,6</sup>. Just as in adults, some of the antihypertensive drugs that may be administered in children are ACE inhibitors, ARBs, calcium antagonists, beta-blockers and diuretics.

Antihypertensive agents used were ACE inhibitors and ARBs, as discussed above, not only for having shown to reduce BP and proteinuria, but also for having a higher level of evidence. There is little information in literature that supports the use of other antihypertensive drugs in children and adolescents once ACE inhibitors or ARBs have failed<sup>4</sup>.

The logical sequence of pharmacotherapeutic management in pediatric patients with CKD/ESRD has not been described. Sometimes the situation is severe and to achieve an adequate hypertension control inevitably leads to nephrectomy. This case may serve to raise the need to establish a treatment schedule in those cases where ACEIs or ARBs have not been effective.



**Figure 1.** Evolution of proteinuria (mg/dl) from birth to the onset of automated peritoneal dialysis.

The optimal management of children and adolescents with CKD/ESRD requires the development of a therapeutic scheme with sufficient scientific evidence to ensure maximum efficiency and safety.

## Bibliography

1. Warady BA, Chadha V. Chronic kidney disease in children: the global perspective. *Pediatr Nephrol.* 2007; 22(12): 1999-2009. doi:10.1007/s00467-006-0410-1.
2. Fernández-Llamazares CM, Manrique-Rodríguez S, Sanjurjo-Sáez M. Drug use safety in paediatrics. *Arch Argent Pediatr.* 2011; 109(6): 510-518.
3. National Kidney Foundation. K/DOQI clinical practice guidelines for chronic kidney disease: evaluation, classification, and stratification. *Am J Kidney Dis.* 2002; 39 (2 Suppl 1): S1-266.
4. Simonetti GD, Bucher BS, Tschumi S, et al. Arterial hypertension and proteinuria in pediatric chronic kidney disease. *Minerva Pediatr.* 2012; 64(2): 171-182.
5. Wühl E, Trivelli A, Picca S, et al. Strict blood-pressure control and progression of renal failure in children. *N Engl J Med.* 2009; 361(17): 1639-1650.
6. Lurbe E, Cifkova R, Cruickshank JK, et al. Management of high blood pressure in children and adolescents: recommendations of the European Society of Hypertension. *J Hypertens.* 2009; 27(9): 1719-1742.
7. Wingen AM, Fabian-Bach C, Schaefer F, et al. Randomised multicentre study of a low-protein diet on the progression of chronic renal failure in children. European Study Group of Nutritional Treatment of Chronic Renal Failure in Childhood. *Lancet.* 1997; 349(9059): 1117-1123.
8. Simonetti GD, Santoro L, Ferrarini A, et al. Systemic hypertension and proteinuria in childhood chronic renal parenchymal disease: role of antihypertensive drug management. *Paediatr Drugs.* 2007; 9(6): 413-418.

Virginia Martínez-Santana<sup>1</sup>, Silvia Marique-Rodríguez<sup>2</sup>, Ana Belén Martínez<sup>2</sup> and Olalla Álvarez<sup>2</sup>

<sup>1</sup>Fundació Hospital de l'Esperit Sant. Barcelona.

<sup>2</sup>Hospital General Universitario Gregorio Marañón. Madrid. España.

\* Autor para correspondencia.

Correo electrónico: vmartinez1@hotmail.com  
(Virginia Martínez-Santana).

Recibido el 6 de febrero de 2014; aceptado el 25 de septiembre de 2014.

DOI: 10.7399/FH.2014.38.6.7328