



## ORIGINALES

# Acquired haemophilia A in a patient with chronic hepatitis C virus infection receiving treatment with pegylated interferon plus ribavirin: role of rituximab

M. Á. Fernández de Palencia Espinosa\*, V. Arocas Casañ, B. Garrido Corro y A. de la Rubia Nieto

*Servicio de Farmacia. Hospital Clínico Universitario Virgen de la Arrixaca. Murcia. España.*

### Abstract

**Background:** Acquired haemophilia is an uncommon condition caused by the development of clotting factor inhibitors. To eliminate them, immunosuppressive therapy with corticosteroids and cytotoxic drugs is required.

**Methods:** We describe a case of rituximab use in acquired haemophilia refractory to conventional therapy in a 63 year old male patient with chronic hepatitis C virus infection who was receiving treatment with pegylated-interferon- $\alpha$ -2a plus ribavirin.

**Results:** After 21 weeks of antiviral therapy, the patient was admitted to hospital with a large haematoma in the abdominal muscles. Factor VIII level was zero and inhibitor titer was 345 Bethesda units. Oral immunosuppressive therapy with methylprednisolone and cyclophosphamide was administered for 1 month, with limited improvement. Therefore, cyclophosphamide was replaced by a four once-weekly dose of intravenous rituximab. Two months later, factor VIII level was normal and inhibitor titer was undetectable.

**Conclusion:** Rituximab may be useful for the treatment of acquired haemophilia resistant to standard therapy.

### Hemofilia adquirida en un paciente con infección crónica por virus de la hepatitis que recibió tratamiento con interferón pegilado y ribavirina: papel de rituximab

#### Resumen

**Antecedentes:** la hemofilia adquirida es un trastorno infrecuente causado por el desarrollo de inhibidores del factor de coagulación. Para eliminarlos, se requiere tratamiento con corticoides y fármacos citotóxicos. **Métodos:** describimos el caso del uso de rituximab en hemofilia adquirida refractaria al tratamiento convencional en un hombre de 63 años con infección crónica por el virus de la hepatitis C y que estaba recibiendo tratamiento con interferón pegilado  $\alpha$ -2a y ribavirina.

**Resultados:** tras 21 semanas de tratamiento antivírico, el paciente fue ingresado en el hospital por un gran hematoma en la musculatura abdominal. La concentración de factor VIII era nula y el título de inhibidor fue de 345 unidades Bethesda. Se administró tratamiento inmunosupresor oral con metilprednisolona y ciclofosfamida durante 1 mes, con escasa mejoría. Así pues, se sustituyó la ciclofosfamida por una dosis semanal de rituximab intravenoso. Dos meses después, la concentración de factor VIII se normalizó y el título de inhibidor era indetectable.

**Conclusión:** Rituximab puede ser útil en el tratamiento de la hemofilia adquirida resistente al tratamiento estándar.

#### KEYWORDS

Acquired haemophilia A; Acquired factor VIII deficiency; Rituximab; Hepatitis C virus; Pegylated interferon alpha-2a

#### PALABRAS CLAVE

Hemofilia adquirida A; Deficiencia adquirida de factor VIII; Rituximab; Virus de la hepatitis C; Interferón pegilado alfa-2a

\* Autor para correspondencia.

Correo electrónico: mafpe13@gmail.com (M<sup>a</sup> Ángeles Fernández de Palencia Espinosa).

## Introduction

Acquired haemophilia A (AHA) is an unusual condition that results from the spontaneous development of autoantibodies against clotting factor VIII (FVIII), leading to inhibition of FVIII binding to von Willebrand factor, to activated factor IX, or to negatively charged phospholipids, and resulting in haemorrhage, principally in soft tissues and systemic bleeding episodes.<sup>1</sup> The underlying mechanisms leading to the production of FVIII autoantibodies are not completely understood but their appearance during interferon (IFN) therapy for chronic hepatitis C virus (HCV) infection has been reported.<sup>2</sup> Prompt diagnosis of this acquired bleeding disorder is essential for appropriate management aimed at controlling haemorrhage and suppressing the inhibitor, both of which are necessary to restore normal haemostasis and to prevent risk of future bleeding episodes.

The diagnosis of AHA is based on the demonstration of an isolated prolongation of activated partial thromboplastin time which is not corrected by mixing patient plasma with normal plasma, associated with reduced FVIII levels and the presence of FVIII inhibitor. Treatment strategies in patients with acquired FVIII inhibitors have two main objectives. During the acute stage, effective control of bleeding is the primary aim which can be achieved with plasma exchange, the administration of human or porcine FVIII, desmopressin, activated prothrombin complex concentrate (APCC) and recombinant human activated factor VII (rFVIIa). Both APCC and rFVIIa have FVIII bypassing activity and are used for the treatment of patients with high titers of inhibitors. The long-term therapeutic goal is the eradication of the inhibitor, thereby curing the condition.<sup>3-5</sup>

Although up to 36% of patients experience a spontaneous disappearance of their autoantibodies within a few months of drug discontinuation, this is unpredictable. To eliminate FVIII inhibitors, immunosuppressive therapy with corticosteroids and cytotoxic drugs, alone or in combination, is regarded as the mainstay of therapy.<sup>1</sup>

## Case Report

A single, non-haemophilic, 63 year old male patient with chronic HCV infection was started on treatment with pegylated-interferon- $\alpha$ -2a (peg-IFN- $\alpha$ -2a), administered subcutaneously at a total dose of 180 mg weekly, plus ribavirin, administered orally at a dose of 800 mg/day in divided doses (400 mg twice daily). It was the first reactivation but he was diagnosed on HCV infection in 1980. Normal levels of albumin, total bilirubin, creatinine, prothrombin time and platelets count indicated compensated chronic liver disease without echographic signs of portal hypertension. For 10 months, patient clinical history was reviewed and the following laboratory investigations were collected: platelets count, haemoglo-

bin, prothrombin time (PT), international normalized ratio (INR), activated partial thromboplastin time (aPTT), patient/control plasma ratio (P/C ratio), fibrinogen, D-dimer, clotting factors levels (FVIII, IX, XI and XII), FVIII inhibitor titers, creatinine, albumin, total bilirubin, aspartate aminotransferase (AST), alanine aminotransferase (ALT) and viral load as HCV-RNA. Analytical data are shown in table 1.

After 15 days of antiviral therapy, he developed a spontaneous haematoma in his left lower eyelid, which resolved without treatment. At week 8 of antiviral therapy, he had an eczematous dermatologic reaction with pruritus and petechias, treated for a week with oral dexametazone, topic methylprednisolone and oral ebastine, with complete resolution. At week 20 of antiviral therapy, patient showed several haematomas in both thighs, glutei and upper limbs, predominantly in the right forearm, secondary to thrombocytopenia and coagulopathy, and he was discharged and made an appointment for analytical control in a week due to he had no previous personal or family history of bleeding. But after four days, he was admitted to hospital for a large haematoma in right lateral abdominal muscles (oblique, external, internal and transversal), coagulopathy (normal PT and prolonged aPTT not corrected with normal plasma after a 2 hour incubation) and acquired haemophilia in high suspicion. Lupus anticoagulant and other autoimmune diseases were excluded. Patient had received 21 weeks of antiviral therapy, which was stopped.

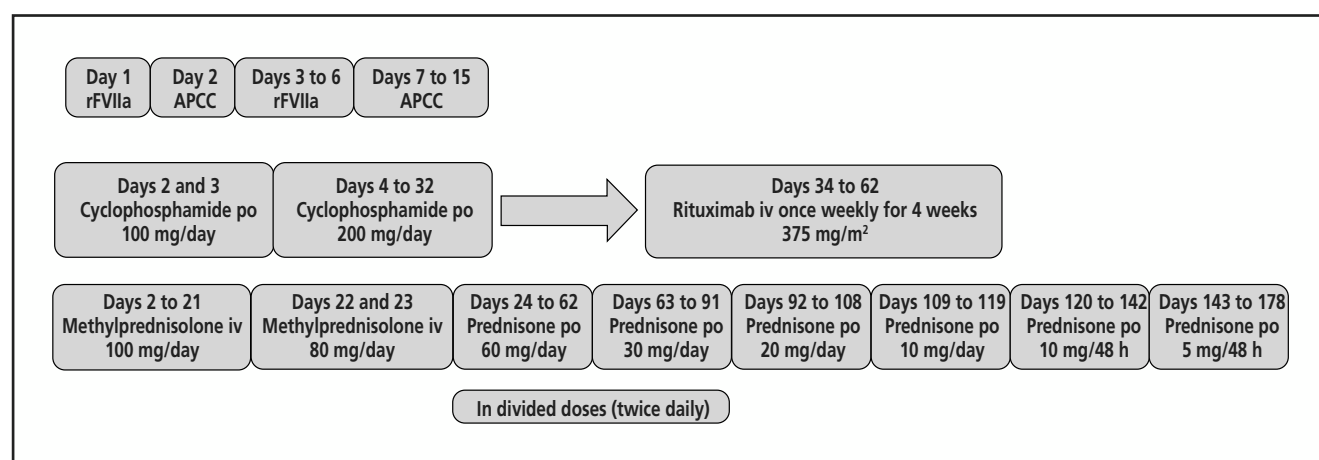
For the acute bleeding stage, treatment with rFVIIa (Novoseven®) was started at a dose of 90 mcg/Kg every 2 hours (patient weight = 100 Kg) during 4 doses, and then, every 4 hours for 4 doses; treatment in the second day was continued with APCC (Feiba®) at a dose of 5,000 U every 8 hours; from third to sixth day, treatment was changed again to rFVIIa, administered at a dose of 9 mg with different dosing interval, receiving a total dose of 166 mg. Due to the lack of new bleeding, treatment was replaced to APCC again for 9 days, at a total dose of 120,000 U, obtaining a good response.

At the same time, immunosuppressive therapy<sup>6</sup> was started in the second day with methylprednisolone and cyclophosphamide. Treatment algorithm is summarized in figure 1. After a month, a slight improvement in FVIII levels and a small reduction in inhibitors were obtained. For this reason, oral cyclophosphamide was replaced by intravenous rituximab, which was used outwit its licensed indications. He received rituximab at 375 mg /m<sup>2</sup> once weekly for 4 weeks and oral prednisone at a dose of 60 mg/day in divided doses (30 mg twice daily) up to the last dose of rituximab; then the dose was gradually tapered over a 16-week period and the agent discontinued. Two months from the start of rituximab therapy, the FVIII level was normal and inhibitor titer undetectable. After resolution, this severe adverse event was reported to our Regional Pharmacovigilance Centre. The patient

**Table 1.** Laboratory investigations. Normal values are indicated below

Diagnosis of reactivation	Antiviral therapy			At admission	Day +6 of immunosuppressive therapy	Day +14 of immunosuppressive therapy	Day +23 of immunosuppressive therapy	Before first dose of rituximab	Before second dose of rituximab	Before third dose of rituximab	Before fourth dose of rituximab	After 8 weeks of rituximab	After 11 weeks of rituximab
	Nov-2010	Week 4	Week 12	Week 21				14-jun	21-jun	28-jun	05-jul	29-aug	20-sep
Platelets ( $\times 10^3$ cell/mL)	155	105	73	91	137	112	90	108	126	140	130	163	
Haemoglobin (g/dL)	14.9	15.0	14.2	9.9	11.5	12.2	11.4	11.1	10.2	11.4	11.5	12.4	
PT (s); INR	10.1; 0.86	12.5; 0.97	11.8; 0.90	11.9; 0.89	10.8; 0.83	13.3; 1.03	12.5; 0.95	11.9; 0.89	12.1; 0.91	11.7; 0.87	12.0; 0.90	11.9; 0.89	12.4; 0.93
aPTT (s); P/C ratio	29.7; 1.04	30.3; 0.95	42.2; 1.41	75.0; 2.68	67.1; 2.31	70.2; 2.42	54.9; 1.89	34.7; 1.20	35.7; 1.23	32.0; 1.10	31.2; 1.08	28.6; 0.99	28.0; 0.97
Fibrinogen (mg/dL)	354	473	486	408	197	209	249	305	333	354	301	458	416
D-dimer (ng/mL)				3.52								890	890
FVIII (U/dL)				0	1	3	2	12	25	ND	ND	138	141
FIX (U/dL)				22	86								
FXI (U/dL)				39	54								
FXII (U/dL)				26	69								
FVIII inhibitor (UB/mL)				Insufficient sample	345	105	105	24	3	ND	ND	Undetectable	ND
Creatinine (mg/dL)	0.86	0.73	0.77	0.66	0.75	0.98	0.69	0.75	0.81	0.76	0.69	0.61	
Albumin (g/dL)	3.8	3.9	4.1	3.7	3.5	3.5		3.5		3.7	3.6		
Total bilirubin (mg/dL)	0.61	0.45	0.41	0.50	0.51	0.61	0.49	0.55	0.42		0.38	0.30	
AST (U/L)	178	89	44	29	39	54	52	91	83	110	112	32	
ALT (U/L)	133	73	34	30	26	30		28	29		43	26	
HCV-RNA (copies/mL)	178,000	42,300	63	< 15					413,000				

Platelets ( $150-350 \times 10^3$  cell/mL), haemoglobin (13.50-17.50 g/dL), prothrombin time (PT, 10.50-15.80 s), international normalized ratio (INR), activated partial thromboplastin time (aPTT, 21-35 s), patient/control plasma ratio (P/C ratio), fibrinogen (150-560 mg/dL), D-dimer (0-275 ng/mL), clotting factors levels (F (FVIII (50-150 U/dL), FX (60-140 U/dL), FXI (60-140 U/dL) and FXII (60-140 U/dL)), FVIII inhibitor titers, creatinine (0.70-1.20 mg/dL), albumin (3.50-5.20 g/dL), total bilirubin (0.05-1.20 mg/dL), aspartate aminotransferase (AST, 5-41 U/L), alanine aminotransferase (ALT, 5-40 U/L) and viral load as HCV-RNA. ND: no data.



**Figure 1.** Treatment algorithm applied to this patient. APCC: activated prothrombin complex concentrate; rFVIIa: recombinant human activated factor VII; po: per oral; iv: intravenous.

has remained completely asymptomatic for the last year. However, he has not received HCV therapy and, therefore, his viral load has relapsed to 17 million copies/mL (last measurement on December 2011) while his ALT and AST levels have remained normal or slightly increased.

Regarding to safety, after two weeks from the last dose of rituximab, patient was readmitted to hospital for 7 seven days affected by right lower leg cellulitis and associated with neutropenia. He was treated with antibiotherapy (imipenem and vancomycin for a week, then levofloxacin and clindamycin for 10 days, and therefore ceftriaxone and cotrimoxazole for two weeks) and 3 doses of filgrastim. He had a previous neuropathic ulcer in his right foot (4<sup>th</sup> and 5<sup>th</sup> fingers), which was complicated by the immunosuppressive therapy. No other adverse effects have been reported. No other acute or delayed relevant side effect or infectious complication occurred.

## Discussion

It's known that both chronic HCV infection and its treatment with IFN can occasionally lead to the development of FVIII autoantibodies. Several cases of acquired factor VIII inhibitors during treatment with IFN- $\alpha$  have been described, but most of these were in patients who had an underlying haematological malignancy.<sup>7,8</sup> Our patient, however, developed FVIII autoantibodies after IFN treatment without having an underlying hereditary coagulopathy, similar to that reported by Schreiber and Bräü.<sup>9</sup> There are also cases of spontaneous development of FVIII inhibitors in HCV infected and HIV/HCV co-infected patients after treatment with IFN.<sup>10-12</sup> Other haematological immune side effects of IFN- $\alpha$  treatment include autoimmune haemolytic anaemia, immune thrombocytopenia, thrombotic thrombocytopenic purpura and increased incidence of cardiolipin antibodies.<sup>13</sup> It is possible that prolonged treatment with IFN increases the propensity for the development of autoantibodies to FVIII,

and this can occur in two ways: autoantibodies may either appear *de novo* or existing antibodies may arise while patients are treated with IFN.

To our knowledge, in Spain and according to FEDRA (Farmacovigilancia Española, Datos de Reacciones Adversas), the database of Spanish Pharmacovigilance System, this is the second case of AHA in a patient treated with IFN- $\alpha$  (the first time was in a patient with melanoma) and the first time in a patient with HCV infection treated with peg-IFN- $\alpha$ -2a. Karch and Lasagna modified by Naranjo algorithm<sup>14</sup> was applied to this case and the causality assessment resulted as *probable*.

Rituximab is a chimaeric mouse-human anti-CD20 monoclonal antibody licensed for the treatment of CD20-positive lymphomas, chronic lymphatic leukemia and rheumatoid arthritis. Its mechanism of action is to cause B-cell depletion in lymph nodes, peripheral blood and bone marrow.<sup>15</sup> Over the last few years, it has been used in off-label conditions in numerous autoimmune diseases including both idiopathic and non-familial thrombotic thrombocytopenic purpura, autoimmune haemolytic anemia<sup>16,17</sup> and mixed cryoglobulinemia. Recent reports also suggest a role for rituximab in the treatment of patients with acquired FVIII inhibitors;<sup>18,19</sup> even a treatment algorithm has been proposed by Aggarwal et al.,<sup>20</sup> with three options according to FVIII inhibitor titer: 1) patients with minimal bleeding and inhibitor levels < 5 Bethesda Units (BU) should be treated with prednisone alone; 2) those with an inhibitor level < 30 BU but with serious bleeding should receive rituximab in combination with prednisone; and 3) those with an inhibitor level  $\geq$  30 BU should be treated with rituximab, prednisone and cyclophosphamide. They also suggested that patients not responding to or relapsing after these therapies may benefit from repeated courses of rituximab or rituximab maintenance therapy. Before rituximab was started, our patient belonged to type 2 regarding this algorithm.

As far as the safety is concerned, our patient suffered an infectious complication due to the immunosuppressive therapy. Recently, several types of side effects have been reported during immunosuppression by the European Acquired Haemophilia Registry (EACH2),<sup>21</sup> such as sepsis, neutropenia, diabetes, and psychiatric illness. For instance, this study suggests that the development of less toxic immunosuppressive regimens would be an important step forward in AHA.

Rituximab treatment of AHA may be cost-effective. Bypassing haemostatic agents are extremely expensive. The estimated cost of treating this severe bleeding episode with recombinant rFVIIa and APCC was € 199,800 without taking into account other costs related to four weeks inpatient treatment. In contrast, treatment with rituximab, which cost € 7,200 for four once-weekly doses, can prevent new bleeding episodes resulting in significant savings in drugs. In conclusion, the administration of rituximab appears to be an effective option for treatment of patients with acquired haemophilia resistant to standard therapies.

## Prior publication

Sent as abstract to EAHP Congress 2012 (Milan). Accepted.

**No financial sources.**

## Conflict of interest

The authors have no conflict of interest to declare.

## Acknowledgements

M<sup>a</sup> José Peñalver Jara. Centro de Farmacovigilancia de la Región de Murcia. Servicio de Ordenación y Atención Farmacéutica. Consejería de Sanidad y Consumo de la Región de Murcia.

## Bibliography

- Boggio LN, Green D. Acquired hemophilia. *Rev Clin Exp Hematol*. 2001;5:389-404.
- Delgado J, Villar A, Jimenez-Yuste V, Gago J, Quintana M, Hernandez-Navarro F. Acquired hemophilia: a single-center survey with emphasis on immunotherapy and treatment-related side effects. *Eur J Haematol*. 2002;69:158-64.
- Sallah S, Aledort L. Treatment of patients with acquired inhibitors. *Thromb Haemost*. 2005;3:595-7.
- Delgado J, Jiménez-Yuste V, Hernández-Navarro F, Villar A. Acquired haemophilia: review and meta-analysis focused on therapy and prognostic factors. *Br J Haematol*. 2003;121(1):21-35.
- Collins PW. Therapeutic challenges in acquired factor VIII deficiency. *Hematology Am Soc Hematol Educ Program*. 2012;2012:369-74.
- Huth-Kühne A, Baudo F, Collins P, Ingerslev J, Kessler CM, Lévesque H, et al. International recommendations on the diagnosis and treatment of patients with acquired hemophilia A. *Haematologica*. 2009;94:566-75.
- English KE, Brien WF, Howson-Jan K, Kovacs MJ. Acquired factor VIII inhibitor in a patient with chronic myelogenous leukemia receiving interferon-alpha therapy. *Ann Pharmacother*. 2000;34:737-9.
- Regina S, Colombat P, Fimbel B, Guerois C, Gruel Y. Acquired inhibitor to factor VIII in a patient with Hodgkin's disease following treatment with interferon-alpha. *Hemophilia*. 2001;7:526-7.
- Schreiber ZA, Braü N. Acquired Factor VIII Inhibitor in Patients With Hepatitis C Virus Infection and the Role of Interferon-alpha: A Case Report. *Am J Hematol*. 2005;80:295-8.
- Dentale N, Fulguro C, Guerra L, Fasulo G, Mazzetti M, Fabbri C. Acquisition of factor VIII inhibitor after acute hepatitis C virus infection. *Blood*. 1997;90:3233-4.
- Herman C, Boggio L, Green D. Factor VIII inhibitor associated with peginterferon. *Haemophilia*. 2005;11:408-10.
- Campos-de-Magalhaes M, Brandao-Mello CE, Elias Pires ML, Fonseca Salgado MC, Barcelo de Brito S, Almeida AJ. Factor VIII and IX deficiencies related to acquired inhibitors in a patient with chronic hepatitis C virus infection receiving treatment with pegylated interferon plus ribavirin. *Hematology*. 2011;16:80-5.
- Stricker RB, Barlogie B, Kiprov BB. Acquired factor VIII inhibitor associated with chronic interferon-alpha therapy. *J Rheumatol*. 1994;21:350-2.
- Naranjo CA, Busto U, Sellers EM, Sandor P, Ruiz I, Roberts EA et al. A method for estimating the probability of adverse drug reactions. *Clin Pharmacol Ther*. 1981;30(2):239-45.
- Stasi R, Brunetti M, Stipa E, Amadori S. Selective B-cell depletion with rituximab for the treatment of patients with acquired hemophilia. *Blood*. 2004;103:4424-8.
- Martínez Velasco E, Gómez Castillo JJ, Fernández Megía MJ, González Joga B, Barreda Hernández D, Gómez Roncero MI. Efectividad de rituximab en púrpura trombocitopénica y anemia hemolítica autoinmune refractarias. *Farm Hosp*. 2007;31:124-7.
- García-Sabina A, Rabuñal Rey R, Martínez-Pacheco R. Revisión sobre el uso de medicamentos en condiciones no incluidas en su ficha técnica. *Farm Hosp*. 2011;35(5):264-77.
- Kain S, Copeland TS, Leahy MF. Treatment of refractory autoimmune (acquired) haemophilia with anti-CD20 (rituximab). *Br J Haematol*. 2002;119(2):578.
- Wiestner A, Cho HJ, Asch AS, Michelis MA, Zeller JA, Peersckhe EI, et al. Rituximab in the treatment of acquired factor VIII inhibitors. *Blood*. 2002;100(9):3426-8.
- Aggarwal A, Grewal R, Green RJ, Boggio L, Green D, Weksler BB, et al. Rituximab for autoimmune haemophilia: a proposed treatment algorithm. *Haemophilia*. 2005;11:13-9.
- Collins P, Baudo F, Knoebl P, Lévesque H, Nemes L, Pellegrini F, Marco P, et al. Immunosuppression for acquired hemophilia A: results from the European Acquired Haemophilia Registry (EACH2). *Blood*. 2012 July 5;120(1):47-55.